

## Venipuncture Technique of the Occipital Venous Sinus in Freshwater Aquatic Turtles

A. Martínez-Silvestre<sup>1</sup>, DVM, MSc, MCVS, D. Perpiñán<sup>2</sup>, DVM,  
I. Marco<sup>2</sup>, DVM, PhD, S. Lavin<sup>2</sup>, DVM, PhD

1. Catalanian Reptile and Amphibian Rehabilitation Center (CRARC, 08783 Masquefa, Barcelona, Spain).
2. Servei d'Ecopatologia de Fauna Salvatge. Facultat de Veterinària. Universitat Autònoma de Barcelona. 08193-Bellaterra. Spain

Blood collection from turtles may be performed from a variety of sites depending on the species. In chelonians, blood may be collected from the heart, jugular vein, brachial vein, femoral vein, dorsal and ventral coccygeal veins, supravertebral vein, orbital sinus, occipital and postoccipital venous sinus, femoral vein and the trimmed toenail (Lloyd and Morris, 1999, Fudge, 2000, Hernandez-Divers and Hernandez-Divers, 2001). The diversity of turtles and tortoises precludes any single dependable venipuncture site, so the clinician may select the best technique for the morphology of individual species (Lloyd and Morris, 1999).

The occipital sinus has been described as a good method for blood sampling in sea turtles (Lloyd and Morris, 1999) and some tortoises, such as the desert tortoise, *Gopherus agassizii*, (Gottdenker and Jacobson, 1995), box turtle, *Terrapene carolina*, (Klingenberg, 1999), Burmese brown tortoise, *Manouria emys*, (Lloyd and Morris, 1999) and pancake tortoise, *Malacochersus tornieri*, (Raphael, et al, 1994). In these species, the supraoccipital crest is small and not prominent (Gaffney, 1979), and an approach to the sinus with the neck extended is feasible (Lloyd and Morris, 1999). However, in freshwater aquatic turtles, this technique has not been described, probably because the supraoccipital crest is larger than in tortoises, which makes it difficult to insert the needle into the venous sinus (Gaffney, 1979).

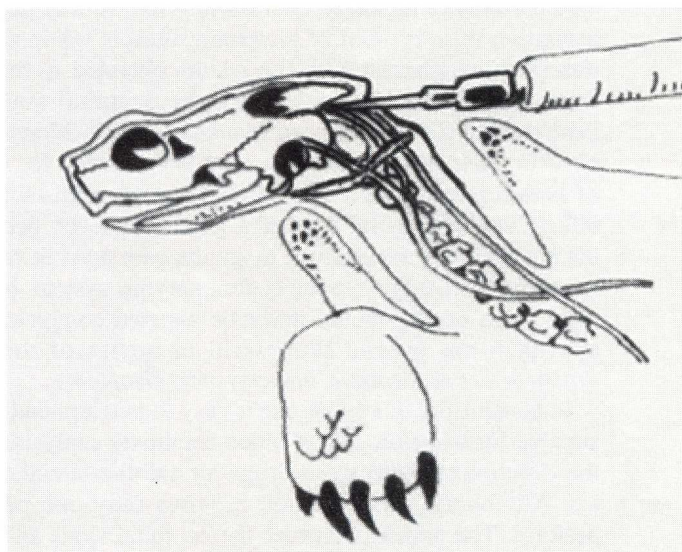
Reptiles have extensive, well developed lymphatic sinuses and vessels, which course adjacent to the venous system (Lloyd and Morris, 1999). The site of blood sample collection may influence hematologic and serum chemistry results because of dilution with lymphatic fluid and/or extravascular fluid (Gottdenker and Jacobson, 1995). In freshwater aquatic turtles, there are no reports describing the potential effects of sample collection site on blood value measurement. In these chelonians, when collecting blood samples, we have observed a clear fluid drawn with blood during venipuncture of the brachial vein, dorsal coccygeal vein and supravertebral (subcarapacial) vein. Based on previous experiences by other authors (Lloyd and Morris, 1999, Hernandez-Divers and Hernandez-Divers, 2001), clear fluid is likely lymph or extravascular fluid which causes dilution of blood samples. While venous blood drawn from the jugular vein is unlikely to be diluted by lymph, in freshwater aquatic turtles the jugular vein is a small vessel which may be difficult to visualize for venipuncture. The ventral coccygeal vein is only used in the snapping turtle, *Chelydra serpentina*, (Lloyd and Morris,

1999). In the heart, there is low risk of hemodilution, but trephination of shell is a complicated, time-consuming technique, which is potentially hazardous for the animal.

In this study, we verified that venipuncture of the occipital venous sinus in turtles can be easily performed with a modified restraint technique. Lymphatic and/or extravascular fluid contamination was not apparent with this technique.

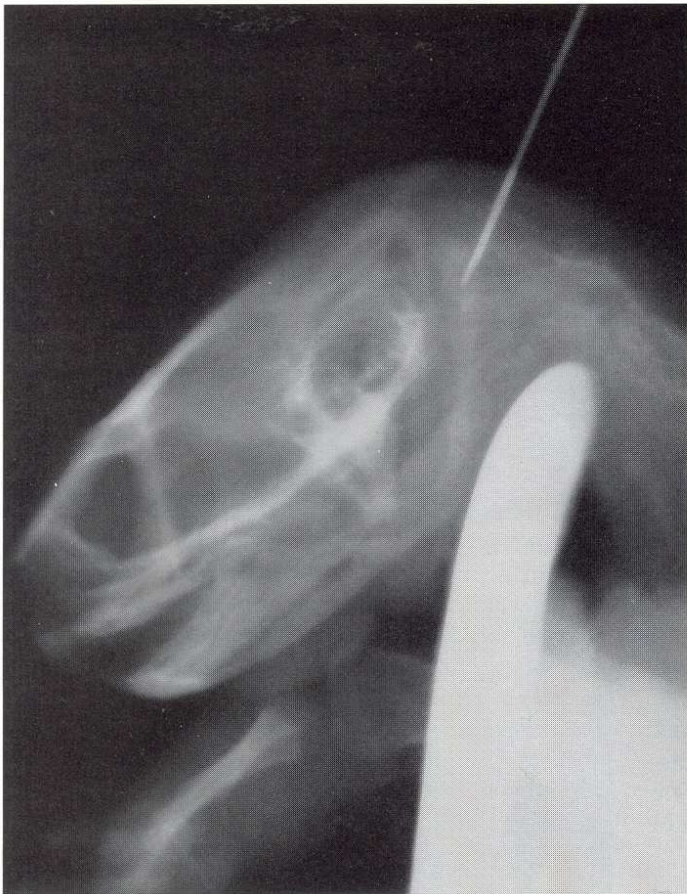**Relevant anatomy** – In freshwater aquatic turtles, the occipital venous sinus is located in the occipital area, ventral to the supraoccipital crest. It is a venous sinus that connects the right and left temporal veins, which arise from the right and left jugular vein respectively (Gaffney, 1979) (Figure 1). Dissections of the occipital and postoccipital regions in the red-eared slider, *Trachemys scripta elegans*, demonstrate the size of the occipital venous sinus is large enough to permit venipuncture.

**Technique** – Position the turtle vertically with the head up. Gentle traction of the head with the dominant hand is used to completely extend the neck. With your nondominant hand, hold the carapace and plastron, leaving the index finger free. Next, direct the head ventrally so that it rests at 90° to the carapace and hold in place with the free index finger of the nondominant hand. The supraoccipital and dorsal horn of the



**Figure 1.** Schematic draw of blood sampling method described in the text. Note the protrusion of supraoccipital crest and dorsal horn of the hyoid apparatus.





**Figure 2.** Lateral radiographic view the needle's position *in situ* when blood can be sampled. Note that foramen magnum is close to the venipuncture site.

hyoid apparatus must be easily palpable with the free (dominant) hand. A 25 ga needle is inserted into the occipital sinus, in the dorsal midline of the neck, just below the hyoid (Figure 2). A 23 ga needle may be necessary in larger turtles.

During venipuncture of the occipital venous sinus in different species of turtles, we have not collected clear fluid. In our clinical observations and dissections, we found the occipital venous sinus to be larger than other veins, so that the risk of aspiration of interstitial or lymphatic fluid is minimal. These observations contrast with the results obtained in the desert tortoise, where the sample from the occipital sinus were hemodiluted (Gottdenker and Jacobson, 1995). Moreover, we observe clinically that this is a good site position for delivery of barbiturates in the euthanasia of turtles, with more rapid effects than the dorsal coccygeal vein. However, because of the proximity of the foramen magnum, care must be taken not to extend the needle into the central nervous system. For safety, a 23 ga needle should never be inserted completely. This approach has proved successful in turtles of the genus *Trachemys*, *Pseudemys*, *Chrysemys* and *Graptemys*.

In conclusion, this technique is easy to perform and appears suitable for hematology and blood chemistry analysis, and for the injection of intravenous drugs for anesthesia and euthanasia. Additionally, this method requires only one person to perform. The authors consider the occipital sinus as the preferred site for venipuncture in freshwater aquatic turtles.

## REFERENCES

- Hernandez-Divers SJ, Hernandez-Divers SM. 2001. Clinical applications of a supravertebral (subcarapacial) vein in chelonians. *Proc ARAV*, 7-8.
- Fudge AM. 2000. Laboratory medicine. Avian and Exotic Pets. WB Saunders, Philadelphia PA:187.
- Gaffney ES. 1979. Comparative cranial morphology of recent and fossil turtles. *Bull Amer Mus Nat His*, 164(2):65-376 (IV).
- Gottdenker NL, Jacobson ER. 1995. Effect of venipuncture sites on hematologic and clinical biochemical values in desert tortoises (*Gopherus agassizii*). *Am J Vet Res*, 56(1):19-21.
- Klingenberg R. 1999. Exotic pet care of box turtles. *Exotic DVM*, 1(2):32-34.
- Lloyd M, Morris P. 1999. Chelonian venipuncture techniques. *Bull ARAV*, 9:26-27.
- Raphael BL, Klemens MW, Moehlman P, Dierenfeld E, Karesh WB. 1994. Blood values in free-ranging pancake tortoises (*Malacochersus tornieri*). *J Zoo Wildl Med*, 25(1):63-67.